

Reactivation of *Clostridium tertium* bone infection 30 years after the Iran–Iraq war

Emilie Viot,¹ Elvire Servien,^{1,2} Frederic Laurent,^{1,2,3} Tristan Ferry,^{1,2,3} on behalf of the Lyon Bone and Joint Infection Study Group

¹Hôpital de la Croix-Rousse, Hospices Civils de Lyon, Lyon, France

²Université Claude Bernard Lyon 1, Lyon, France

³Centre International de Recherche en Infectiologie, CIRI, Inserm U1111, CNRS UMR5308, ENS de Lyon, UCBL1, Lyon, France

Correspondence to

Dr Tristan Ferry,
tristan.ferry@univ-lyon1.fr

Accepted 27 January 2015

DESCRIPTION

A 40-year-old man presented with left knee pain (during night and day) for 3 weeks. He has a history of left knee injury from shrapnel contracted in 1987 during the Iran–Iraq war (the patient did not experience cellulitis, loss of function or any other symptom immediately following the injury). At the time of physical examination 30 years later, a small curved scar facing the tibial tuberosity was seen, without fistula, without local signs of inflammation and without knee arthritis. X-ray showed bony lysis of the proximal tibia around a foreign metal object (figure 1A). CT scan combined with granulocyte-labelled scintigraphy showed recruitments of polymorphonuclear cells within the bone lysis (figure 1B). Tibiotomy was performed to extract the piece of shrapnel. A gentamicin-impregnated spacer was used to fill the bone cavity, which was later removed. Two of the four bone samples revealed late growth of *Clostridium tertium*, which was susceptible to penicillin. The patient received amoxicillin and pristinamycin during a course of 12 months. The evolution was favourable (figure 1C).

C. tertium is a non-toxic aerotolerant Gram-positive bacillus that forms spores in aerobic conditions. It is often misidentified with *Corynebacterium* spp, *Lactobacillus* spp or *Bacillus* spp. *C. tertium* could be responsible for soft tissue infection or bacteraemia in immunocompromised

hosts.^{1,2} Bone and joint infection due to *C. tertium* is rarely described in the literature. Greidlein *et al*³ reported 37 cases of septic arthritis due to the *Clostridium* species, including one case of *C. tertium* arthritis, which was also associated with a metal fragment. The management of implant-associated *C. tertium* infections requires extraction of the foreign body and prolonged antimicrobial therapy.

Learning points

- ▶ *Clostridium tertium* could be responsible for late metal fragment bone and joint infection.
- ▶ Late *C. tertium* metal fragment bone and joint infections requires a multidisciplinary management.
- ▶ Late *C. tertium* metal fragment bone and joint infections requires metal extraction and prolonged antimicrobial therapy for healing.

Collaborators Lyon Bone and Joint Infection Study Group: Physicians—TF, Thomas Perpoint, André Boibieux, François Biron, Florence Ader, Julien Saison, Florent Valour, Fatima Daoud, Johanna Lippman, Evelyne Braun, Marie-Paule Vallat, Patrick Miaillhes, Christian Chidiac and Dominique Peyramond. Surgeons—Sébastien Lustig, Philippe Neyret, Olivier Reynaud, Caroline Debette, Adrien Peltier, Anthony Viste, Jean-Baptiste Bérard, Frédéric Dalat, Olivier

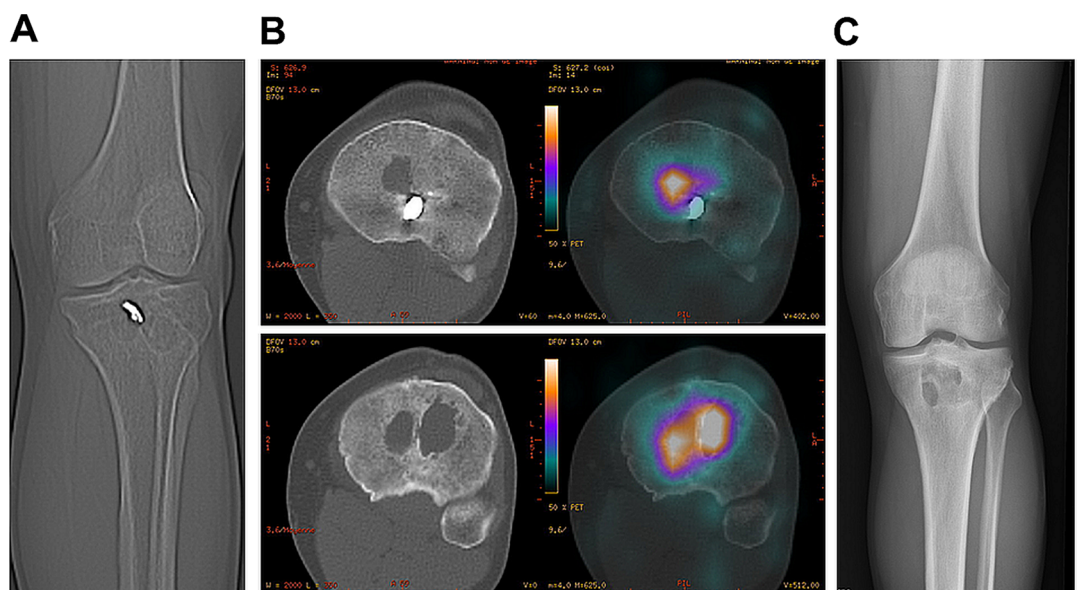


Figure 1 (A) X-ray of the tibia showing the foreign body and the bone lysis. (B) CT scan combined with granulocyte-labelled scintigraphy showing a recruitment of polymorphonuclear cells within the bone lysis. (C) X-ray of the tibia 3 years after the treatment.



To cite: Viot E, Servien E, Laurent F, *et al*. *BMJ Case Rep* Published online: [please include Day Month Year] doi:10.1136/bcr-2014-209169

Cantin, Romain Desmarchelier, Michel-Henry Fessy, Cédric Barrey, Francesco Signorelli, Emmanuel Jouanneau, Timothée Jacquesson, Pierre Breton, Ali Mojallal, Fabien Boucher and Hristo Shipkov. Microbiologists—FL, François Vandenesch, Jean-Philippe Rasigade and Céline Dupieux. Imaging—Loïc Bousset and Jean-Baptiste Pialat. Nuclear Medicine—Isabelle Morelec, Marc Janier and Francesco Giammarile. PK/PD specialists—Michel Tod, Marie-Claude Gagnieu and Sylvain Goutelle. Clinical Research Assistant—Eugénie Mabrut.

Contributors EV and TF wrote the case; ES participated in the patient's care and the literature review; FL participated to the literature review.

Competing interests None.

Patient consent Obtained.

Provenance and peer review Not commissioned; externally peer reviewed.

REFERENCES

- 1 Fujitani S, Liu CX, Finegold SM, *et al.* *Clostridium tertium* isolated from gas gangrene wound; misidentified as *Lactobacillus* spp initially due to aerotolerant feature Shigeki. *Anaerobe* 2007;13:161–5.
- 2 Vanderhofstadt M, André M, Lonchay C, *et al.* *Clostridium tertium* bacteremia: contamination or true pathogen? A report of two cases and a review of the literature. *Int J Infect Dis* 2010;14(Suppl 3):e335–7.
- 3 Gredlein CM, Silverman ML, Downey MS. Polymicrobial septic arthritis due to *Clostridium* species: case report and review. *Clin Infect Dis* 2000;30:590–4.

Copyright 2015 BMJ Publishing Group. All rights reserved. For permission to reuse any of this content visit <http://group.bmj.com/group/rights-licensing/permissions>.

BMJ Case Report Fellows may re-use this article for personal use and teaching without any further permission.

Become a Fellow of BMJ Case Reports today and you can:

- ▶ Submit as many cases as you like
- ▶ Enjoy fast sympathetic peer review and rapid publication of accepted articles
- ▶ Access all the published articles
- ▶ Re-use any of the published material for personal use and teaching without further permission

For information on Institutional Fellowships contact consortiasales@bmjgroup.com

Visit casereports.bmj.com for more articles like this and to become a Fellow